Prof. Dr. Mehmet Salih Bilal

CCTGA'da Double Switch Operasyonu

Medicana International Istanbul Hospital



16. Ulusal Pediatrik ve Kalp Cerrahisi Kongresi'nde yapmakta olduğum sunumumda kullandığım bilgi, veri, görüşler, araştırmalar, makaleler ve bunların dayandığı bilgi, çalışma ve yayınlar ve diğer bilimsel görüşlerin sunumumda kullanılması ile ilgili sorumluluk şahsıma ait olup, herhangi bir çıkar çatışmam bulunmamaktadır.

CCTGA

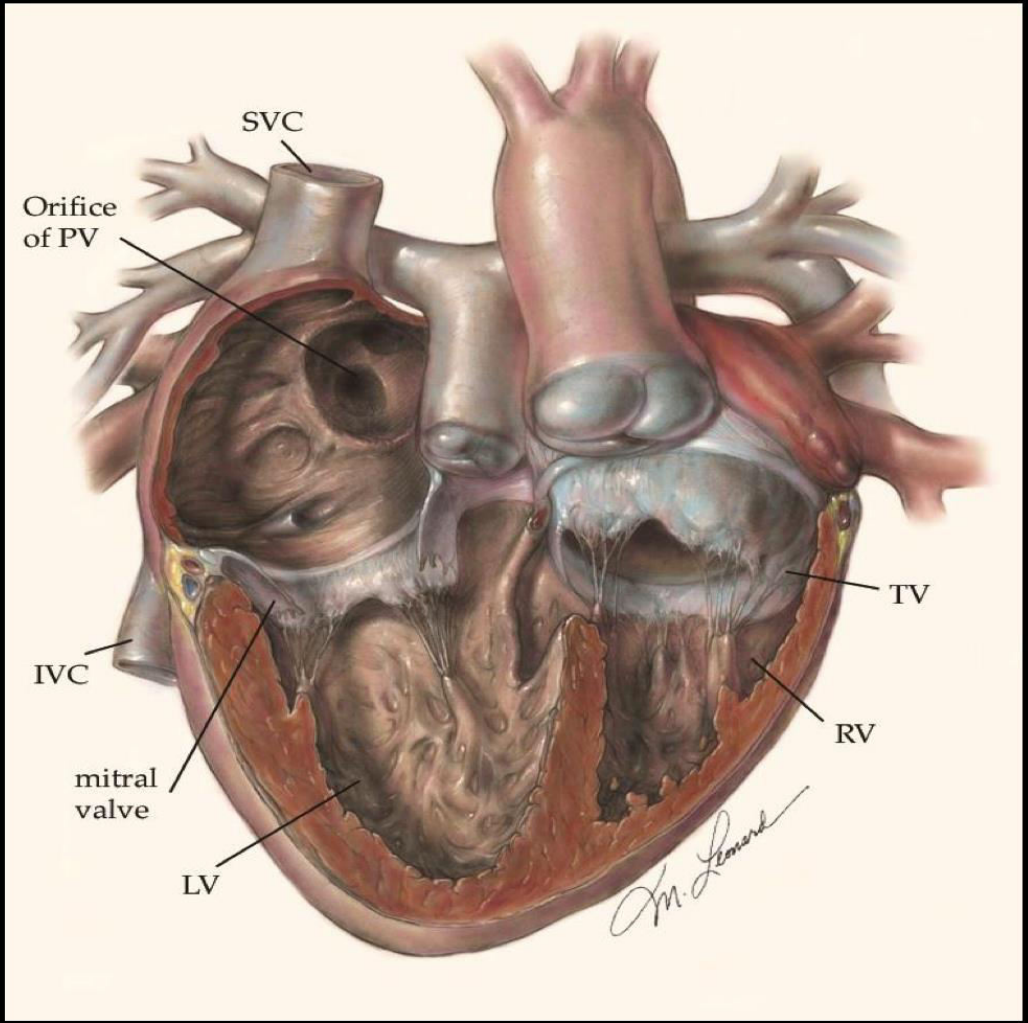

CCTGA

- Teorik olarak normal bir dolaşım söz konusu olsa da, sık görülen ilave kardiyak anomaliler nedeniyle durum genellikle normal değildir.
- Hatta ilave kardiyak anomalisi olmayan hastalarda bile sistemik dolaşımdaki sağ ventrikül ve triküspid kapak zamanla problem yaratır.

CCTGA'yı komplike eden anatomik özellikler

- Dekstrokardi +/- situs anomalileri(%25)
- LVOTO > %50 (Multilevel)
- VSD (%50-80)
  - Multipl
  - Remote
- TV anomalileri (%25-90)
- Straddling ve overriding AV kapaklar
- Ventriküler hipoplazi
- Koroner anomaliler
- Komplet kalp bloku

- *Karl TR. Ann Pediatr Cardiol 2011;4(2):103-110*

Major dörtlü

- Ventriküler septal defekt
- Pulmoner stenoz
- Sistemik triküspit kapak anomalisi ve yetersizliği
- Komplet kalp bloku

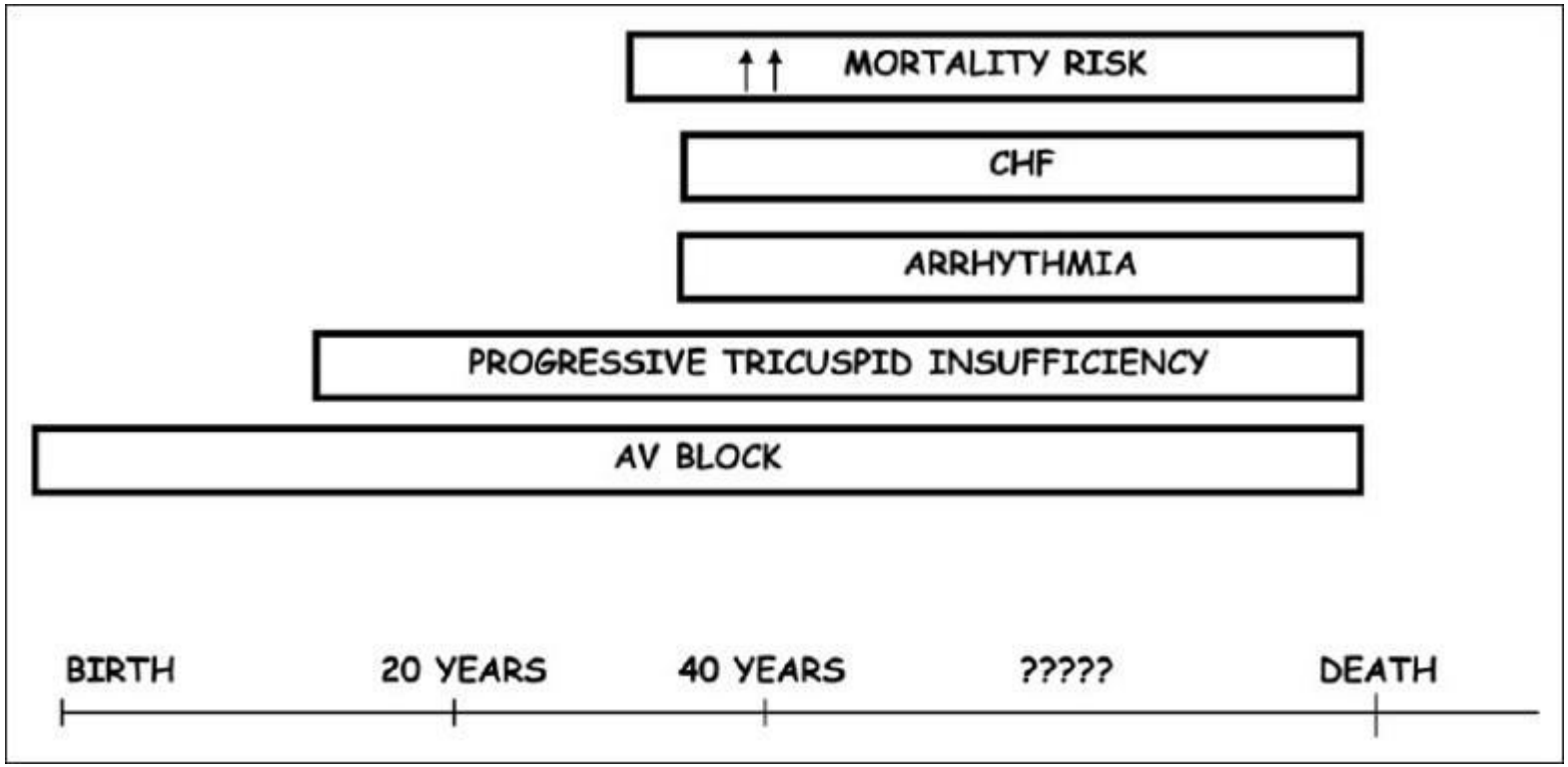
MORTALITY RISK
CHF
ARRHYTHMIA
PROGRESSIVE TRICUSPID INSUFFICIENCY
AV BLOCK
BIRTH
20 YEARS
40 YEARS
?????
DEATH

Cerrahi seçenekler

- Sistemik RV:
  - TY için nihai tedavi olarak PAB
  - Neonatal PAB
  - Konvansiyonel (Fizyolojik) tamir
  - 1.5 Ventrikül fizyolojik tamir (Mavroudis)
  - TVR
  - Multi-site pacing
- Sistemik LV:
  - Senning +ASO
  - Senning + Rastelli
  - Senning + Patrick Mc Goon
  - Senning + Mod. Nikaidoh
  - 1.5 Ventrikül anatomik tamir
- Sistemik RV+LV
  - Fontan
- Cerrahi yapmamak

Konvansiyonel tamir sonuçları

- Sano ve ark.:10 yılda
  - Mortalite %17, TY%71, %50 sistemik ventr. disfonksiyonu
- Termington ve ark. 10 yılda %30 mortalite
- Multicenter çalışma(2005) 15 yıllık survi %61

CCTGA ' da anatomik tamir 'double switch'

- Atrial ve ventriküler outflow'ların switch edilmesiyle AV ve VA konkordans elde edilmesi, yani LV'nin sistemik dolaşımda çalışmasının sağlanmasıdır.
- Bu arada eşlik eden lezyonlar da düzeltilir (VSD, PS/PA, TY, kalp bloku)

Atrial outflow switch yöntemleri

- Senning baffle
- Mustard baffle
- Hemi-Mustard + Bidirectional Glenn

Ventriküler outflow switch yöntemleri

- Arteryel switch
- Rastelli LV-Ao baffle+RV-PA konduit
- Aortik translokasyon + RV-PA konduit

CCTGA

arterial switch completed
measuring hemi-Mustard PTFE patch

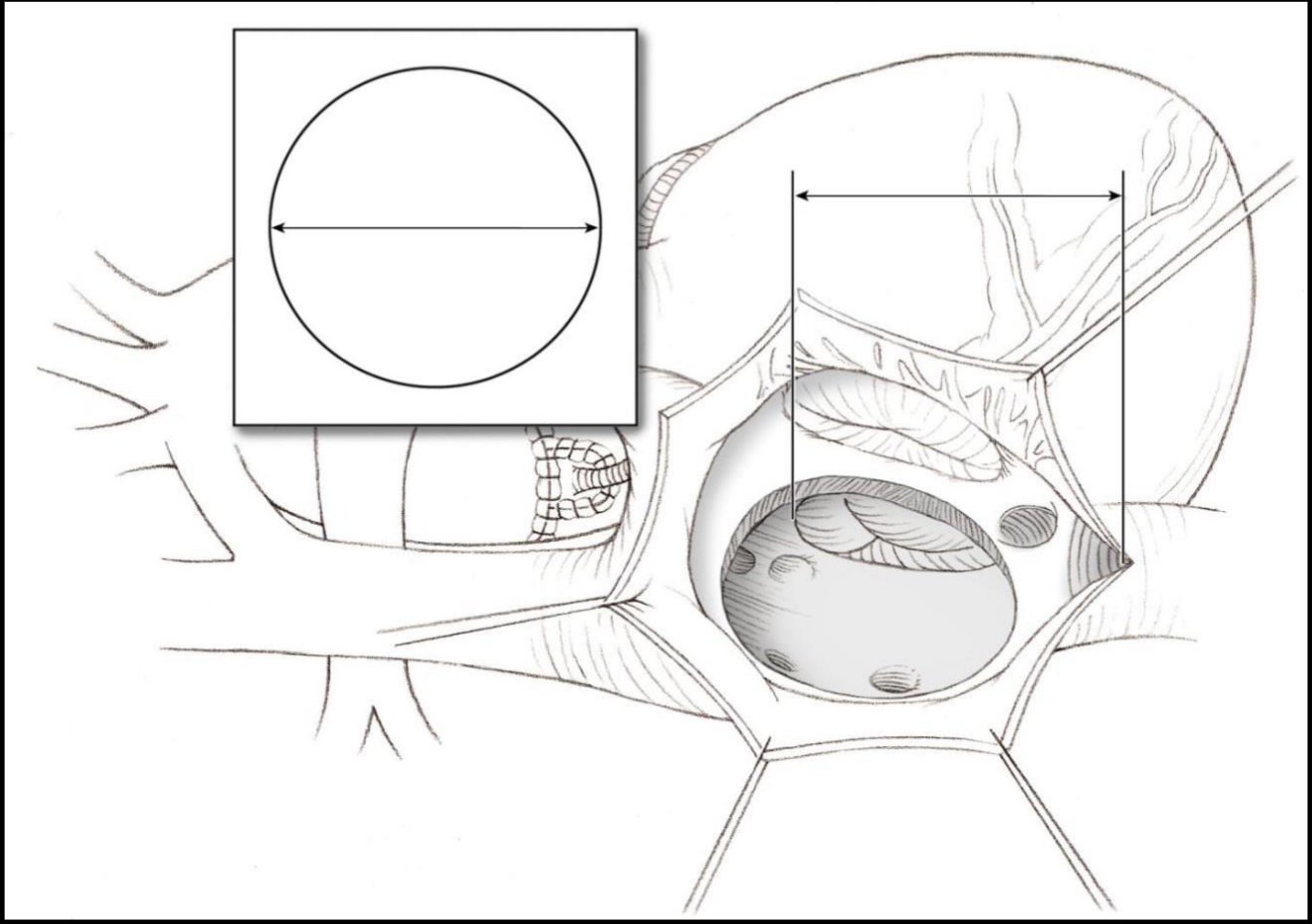

CCTGA

arterial switch completed
hemi-Mustard PTFE patch completed

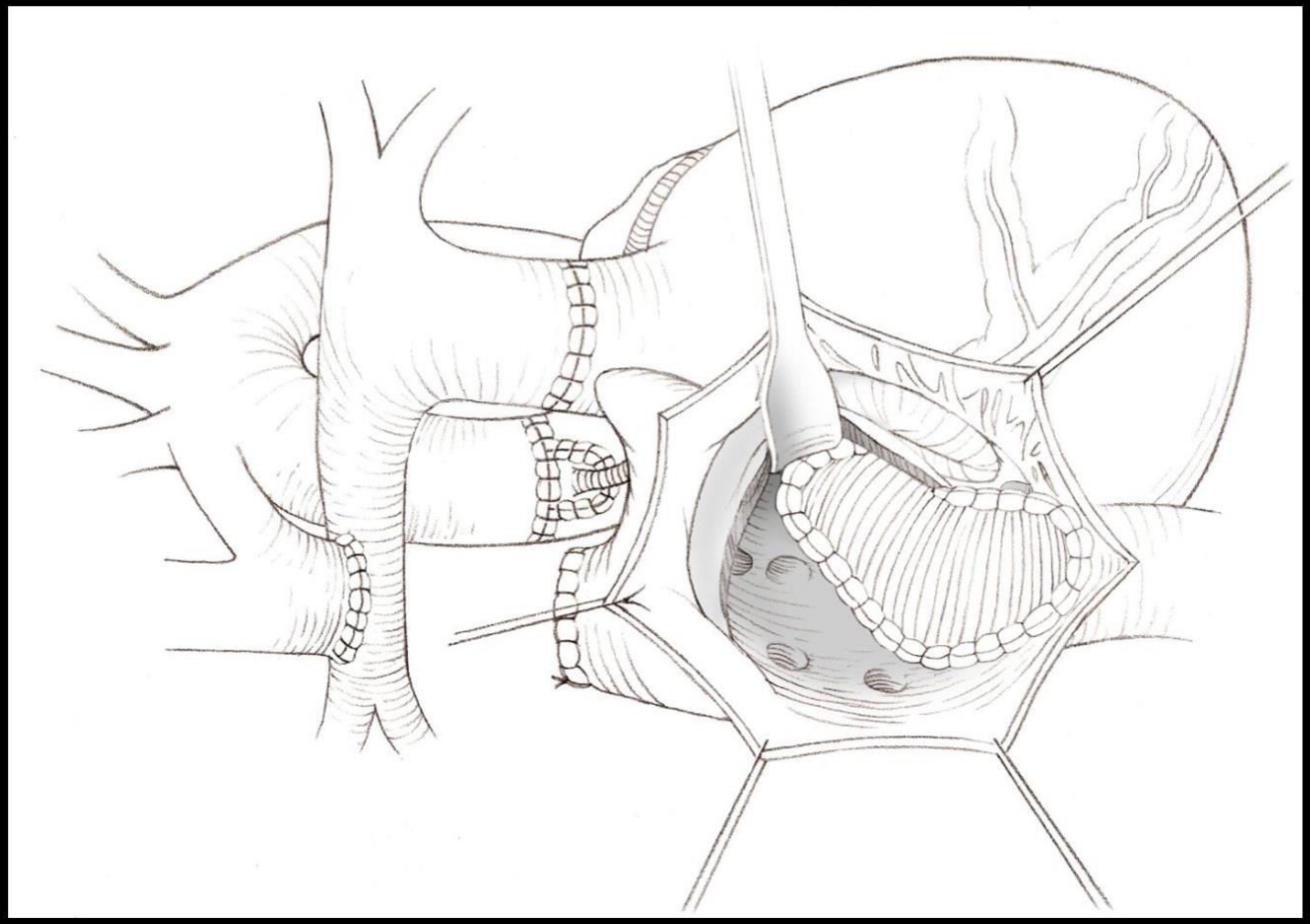

Arterial-Atrial Switch (AAS)

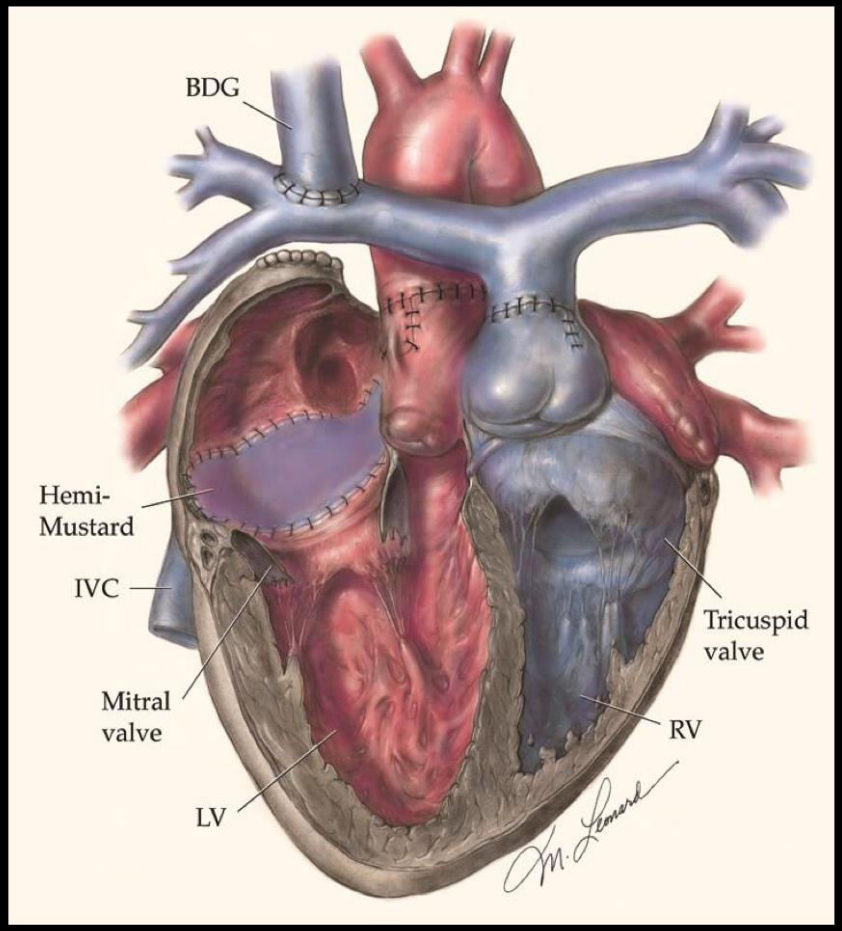

Rastelli-Atrial Switch (RAS)

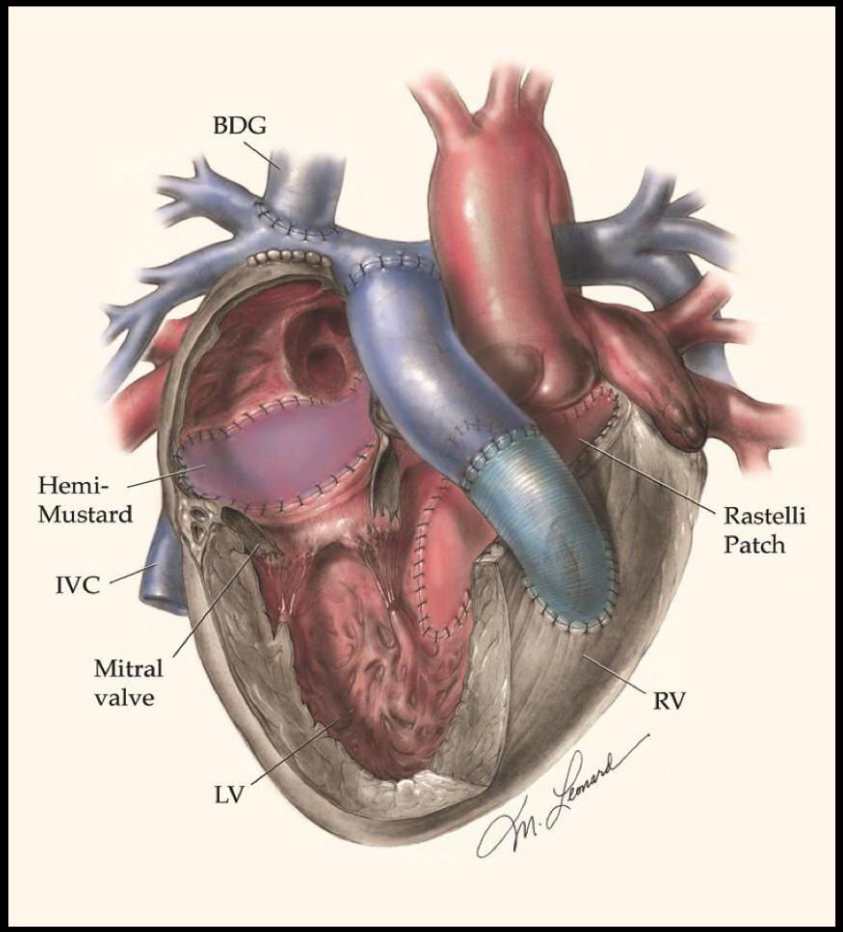

RVOT revision

hemi-Mustard and BDG vs conventional atrial switch

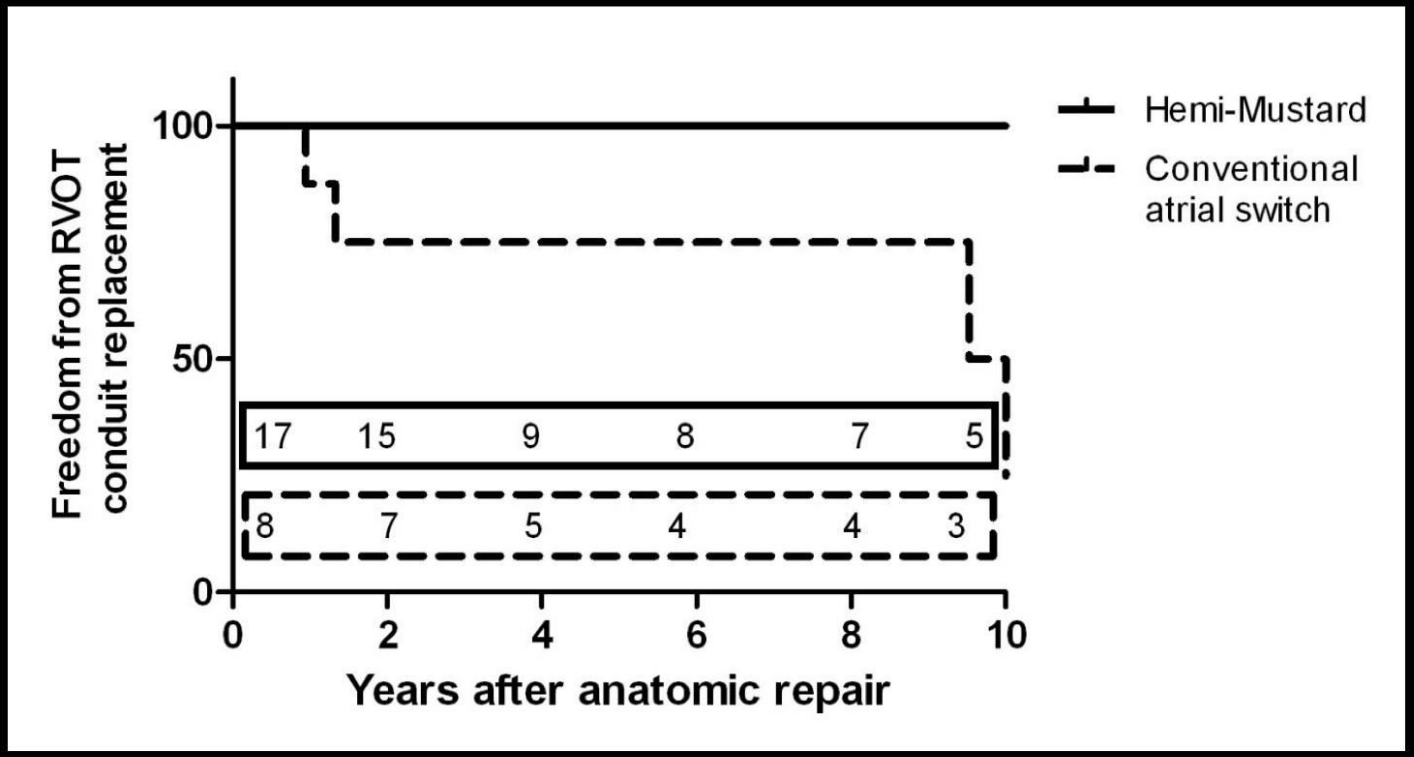

- **Hemi-Mustard group: 100% 10-yr freedom from RVOT intervention**
- **Conventional atrial switch: 75% 5-yr and 50% 10-yr**
- **Hemi-Mustard lower risk of RVOT reintervention (p=0.019)**

Hemi-Mustard + Glenn

- RV-PA konduitin ömrünü uzatır. Daha küçük konduit konulmasına izin verir ve sternum bası ihtimali azalır.
- Sağ ventrikül disfonksiyonu varsa yükünü azaltır.
- Triküspit kapak displazik ise yetersizliğini hafifletir.
- SVC obstrüksiyonu ihtimalini kaldırır ve pulmoner baffle komplikasyonlarını minimize eder.
- Atriyal sütür hatları azaldığından sinüs nod disfonksiyonu ve atrial aritmiler üzerinde olumlu etki yaratır.
- Özellikle situs solitus+ dekstrokardi ve situs inversus vakalarında atriyal switch'i kolaylaştırır.
- Aort klemp zamanını kısaltır.

Outcomes of definitive surgical repair for congenitally corrected transposition of the great arteries or double outlet right ventricle with discordant atrioventricular connections: risk analyses in 189 patients.

Shin'oka T, Kurosawa H, Imai Y, Aoki M, Ishiyama M, Sakamoto T, Miyamoto S, Hobo K, Ichihara Y.
Department of Cardiovascular Surgery, The Heart Institute of Japan, Tokyo Women's Medical University, Tokyo, Japan.

This study was undertaken to compare long-term results of various types of surgical repairs for either congenitally corrected transposition of the great arteries or double outlet right ventricle with discordant atrioventricular connections, and to analyze the risk factors that affect early and late mortality and reintervention.
Between January 1972 and September 2005, a total of 189 patients (median age 8.3 years, range 2 months to 47 years old) with congenitally corrected transposition of the great arteries or double outlet right ventricle with discordant atrioventricular connections underwent definitive repairs. The definitive repairs comprised a conventional repair (atrial septal defect, or ventricular septal defect closure with or without pulmonary stenosis release, or isolated tricuspid valve surgery) in 36 patients (group I), conventional Rastelli in 31 patients (group II), double-switch operation (atrial switch plus arterial switch) in 15 patients (group III), atrial switch plus intraventricular rerouting (with or without extracardiac conduits) in 69 patients (group IV), and a Fontan-type repair in 38 patients (group V). The mean follow-up period was 10.1 years. Hospitalization and late mortality and reoperation were indicated as events. Risk factors for these events were analyzed by logistic regression for hospital death and a Cox proportional hazards model for late events.

J Thorac Cardiovasc Surg 2007 May;133(5):1318-28

RESULTS:

The Kaplan-Meier survival including hospital and late mortality was 62.4% at 32 years in group I, 78.5% at 27 years in group II, 74.5% at 15 years in group III, 80% at 16 years in group IV, and 79.3% at 22 years in group V. The reoperation-free ratio was 64.2% in group I, 76.6% in group II, 84.4% in group III, 89.6% in group IV, and 91.3% in group V. Risk analyses showed that the risk for hospital death was preoperative in patients with more than moderate tricuspid regurgitation and a cardiopulmonary bypass time of more than 240 minutes. A risk for late mortality was the presence of tricuspid regurgitation. Risks for reoperation were preoperative cardiomegaly, preoperative tricuspid regurgitation of more than grade II, ventricular septal defect enlargement, and body weight less than 10 kg. Risks for pacemaker implantation, as indicated by multivariate analysis, were ventricular septal defect enlargement during operation and age less than 3 years.

CONCLUSIONS:

There were no statistical differences between long-term survival rates of patients who underwent conventional surgical repair versus those of patients who underwent anatomic surgical repair. Results of conventional repair were satisfactory except in patients with significant tricuspid regurgitation. Results of anatomic repair were also satisfactory even for patients with significant tricuspid regurgitation, and therefore, anatomic repair should be the procedure of choice for those patients

J Thorac Cardiovasc Surg 2007 May;133(5):1318-28

The role of the Fontan operation in the treatment of congenitally corrected transposition of the great arteries.

Karl TR.

Source

Department of Paediatric Cardiac Surgery, Queensland Paediatric Cardiac Service, Mater Children's Hospital, Brisbane, Australia.

Abstract

Congenitally corrected transposition of the great arteries (ccTGA) is a complex cardiac anomaly with an unfavorable natural history. Surgical treatment has been available for over 50 years. Initial procedures used for ccTGA did not correct atrio-ventricular discordance, leaving the right ventricle in systemic position. In the past two decades anatomic repair has been considered to be a better option. Many cases subjected to anatomic repairs would also be suitable for the Fontan strategy, which probably has a lower initial risk. The rationale for use of the Fontan operation in management of congenitally corrected transposition is discussed in this review, with comparisons to other strategies

Ann Pediatr Cardiol 2011;4(2):103-110

	Physiologic	Anatomic	Fontan
Technical complexity	++	++++	+
Operative mortality	++	++	+
Late atrial baffle problems	n/a	+	n/a
Late tricuspid insufficiency	+++	+	??
Heart block	+++	++	+
Systemic ventricle	Right	Left	Both
Ventricular retraining	n/a	Selected cases with intact ventricular septum	n/a
Septation complexity	+	+++ (for Rastelli)	n/a
Late morbidity or mortality	++++	++	+
Late functional disability	++++	+	+
Reoperation probability	++++ (for LV-PA conduit)	++++ (for RV-PA conduit)	+

Karl TR. Ann Pediatr Cardiol 2011;4(2):103-110

Long-term prognosis of double-switch operation for congenitally corrected transposition of the great arteries.

Hiramatsu T, Matsumura G, Konuma T, Yamazaki K, Kurosawa H, Imai Y.
Department of Cardiovascular Surgery, Tokyo Women's Medical University, Tokyo, Japan

OBJECTIVES:
Recently, the double-switch operation for congenitally corrected transposition of the great arteries has become the procedure of choice in our institute; however, the long-term follow-up is uncertain.
METHODS:
From 1983 to 2010, 90 patients with congenitally corrected transposition of the great arteries underwent the double-switch operation, which comprised of an atrial switch plus intraventricular rerouting (with or without extracardiac conduits) in 72 patients (group I), and an atrial switch plus arterial switch in 18 patients (group II). The mean age at operation was 7.4 years old in group I vs. 4.3 years old in group II. The mean follow-up period was 12.9 years in group I vs. 10.9 years in group II. Hospital and late mortality, reoperation, arrhythmia and NYHA status were analysed retrospectively.
RESULTS:
The Kaplan-Meier survival, including hospital and late mortality at 20 years, was similar (75.7% in group I vs. 83.3% in group II). The freedom from reoperation was 77.6% in group I (redo-Rastelli in five patients, subaortic stenosis resection in three, tricuspid valve replacement in one and mitral valve plasty in one) vs. 94.1% in group II ($P < 0.05$ vs. group I; aortic valve replacement in one). The freedom from arrhythmia was 57.1% in group I vs. 78.6% in group II ($P < 0.05$ vs. group I). The ratio of NYHA class I to II at outpatient clinic was similar (86% in group I vs. 86% in group II).
CONCLUSIONS:
The long-term prognosis of the double-switch operation for congenitally corrected transposition of the great arteries was acceptable. In particular, an atrial switch plus arterial switch could be performed with low morbidity, and it should be considered as the optimal procedure.

Eur J Cardiothorac Surg 2012 Dec;42(6):1004-8

Aksi görüş

- Rastelli hastaları arteryel switch hastalarından genellikle daha iyi seyreder. Tek problem zamanla gelişen konduit disfonksiyonudur ve BDG kullanılarak bu geciktirilebilir.
- Arteryel switch hastaları sıklıkla LV training'i yönünden belirsizlikle karşı karşıyadır ve ayrıca pulmoner band ile ilişkili aort yetersizliği geliştirebilirler.

Mainwaring RD, Hanley F.Operative techniques in Thoracic and Cardiovascular Surgery,2011

World Journal for Pediatric and Congenital Heart Surgery
2017, Vol. 8(2) 203-209

DOI: 10.1177/2150135116683939
journals.sagepub.com/home/pch
SAGE

Left Ventricular Retraining and Double Switch in Patients With Congenitally Corrected Transposition of the Great Arteries

Ali N. Ibrahimiye, MD[1], Richard D. Mainwaring, MD[1], William L. Patrick, BS[1], Laura Downey, MD[2], Vamsi Yarlagadda, MD[3], and Frank L. Hanley, MD[1]

Abstract

Purpose: Congenitally corrected transposition of the great arteries (CC-TGA) is a complex form of congenital heart defect with numerous anatomic subgroups. The majority of patients with CC-TGA are excellent candidates for a double-switch procedure. However, in the absence of an unrestrictive ventricular septal defect or subpulmonary stenosis, the left ventricle (LV) may undergo involution and require retraining prior to double switch. The purpose of this study was to review our experience with patients having CC-TGA who required LV retraining prior to a double-switch procedure. **Methods:** This was a retrospective review of 24 patients with CC-TGA who were enrolled in an LV retraining program in preparation for a double-switch procedure. The median age at the time of enrollment for retraining was 11 months (range 1 month-24 years). The average left ventricle to right ventricle pressure ratio was 0.39 $\pm$ 0.07 prior to intervention. All 24 patients underwent placement of an initial pulmonary artery band (PAB) for LV retraining. **Results:** Eighteen (75%) of the 24 patients underwent a double-switch procedure with no operative mortality. Of these 18 patients, 9 had a single PAB and 9 required a second band for retraining. Six patients have not undergone a double-switch procedure to date. Five patients are good candidates for a double switch and are 2 weeks, 3 weeks, 4 weeks, 8 months, and 35 months since their last PAB. One patient died from a noncardiac cause 26 months after PAB retightening. The 18 patients who underwent a double switch were followed for an average of 5 $\pm$ 1 years (range 0.1-10.3 years). There has been no late mortality, and only 2 patients required further reinterventions. **Conclusion:** The data demonstrate that LV retraining has been highly effective in this select group of patients with CC-TGA. The data also demonstrate that the results of the double-switch procedure have been excellent at midterm follow-up. These results suggest that LV retraining and double switch offer a reliable strategy option for patients with CC-TGA.

Table 1. Assessment of the Left Ventricular Preparedness for a Double Switch.

1	Left ventricular pressure	90% of Systemic pressure
2	Left ventricular systolic function	Ejection fraction >55%
3	Left ventricular end diastolic pressure	Less than 12 mm Hg
4	Mitral valve function	Mild or less insufficiency
5	Left ventricular mass (by MRI)	>50 g/m^2 (in children) >65 g/m^2 (in adults)

Abbreviation: MRI, magnetic resonance imaging.

Tricuspid regurgitation following double switch

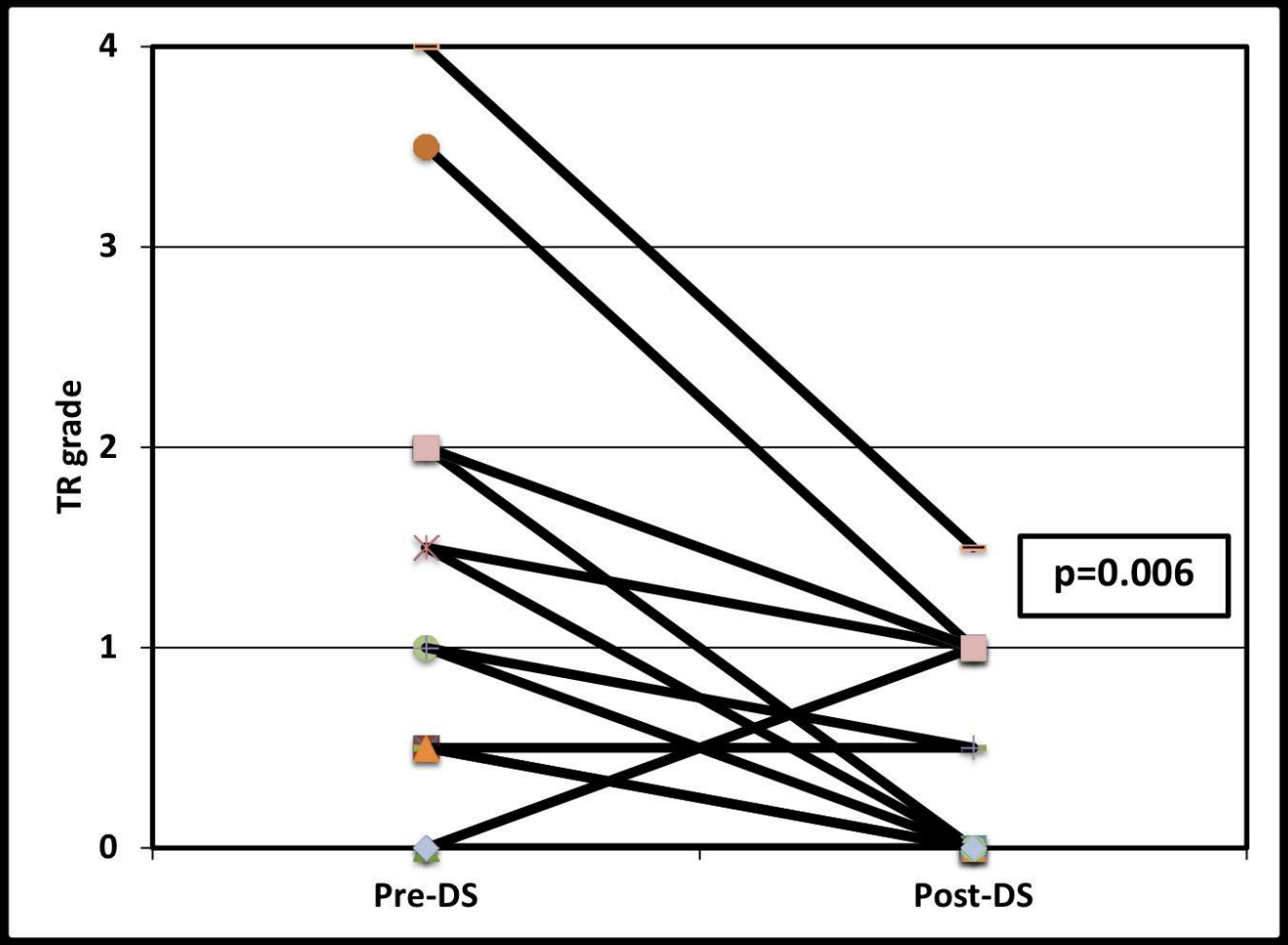

Table 3

Meta-analysis of outcome data for anatomic repair of ccTGA

Publication	Origin	N	Hospital mortality (95% CI)
Karl *et al* 1997	Melbourne	14	7% (1.6-32)
Gaies *et al* 2009	Ann Arbor	65	13.8% (8-24)
Mohamedou *et al* 2009	Paris	20	0% (0-16)
Imai et al 1997	Tokyo	44	9% (3-21)
Langley *et al* 2003	Birmingham	54	5.6% (2-15)
Bautista-Hernandez 2006	Boston	44	4.5% (2-15)
Alghamdi *et al* 2006	Toronto (meta-analysis)	94	6.4% (3-13)
Duncan *et al* 2005	Cleveland	73	1.5% (0.3-7)
Sharma *et al* 2009	Bangalore	68	15% (8-25)

Karl TR. Ann Pediatr Cardiol 2011;4(2):103-110

Double Switch Procedure and Surgical Alternatives for the Treatment of Congenitally Corrected Transposition of the Great Arteries

Mehmet Salih Bilal, M.D.,* Mustafa Kemal Avşar, M.D.,* Özgür Yıldırım, M.D.,* Arda Özyüksel, M.D.,† Cenap Zeybek, M.D.,‡ Osman Küçükosmanoğlu, M.D.,‡ and Şener Demiroluk, M.D.§

**Department of Cardiovascular Surgery, Medicana International Hospital, Istanbul, Turkey; †Department of Cardiovascular Surgery, Medipol University, Istanbul, Turkey; ‡Department of Pediatric Cardiology, Medicana International Hospital, Istanbul, Turkey; and §Department of Anesthesiology, Medicana International Hospital, Istanbul, Turkey*

ABSTRACT ***Background:*** **We present our experience with the double switch operation in sixteen patients with congenitally corrected transposition of the great arteries.** ***Methods:*** **We enrolled 16 patients with congenitally corrected transposition of the great arteries operated by a single surgeon between 1995 and 2015. The mean age was 25 months (range 4 to 72 months) and the mean body weight was 8.9 kg (range 4.3 to 19 kg) at the time of operation.** ***Results:*** **We encountered seven patients with moderate to severe tricuspid regurgitation, five of which had Ebstein anomaly. We performed a combination of atrial and arterial switch procedures in 11 cases, one of which had a concomitant coarctation of the aorta that was repaired along with the double switch procedure. Atrial switch and the Rastelli procedures were performed in three cases with concomitant pulmonary stenosis. A combination of arterial switch, Hemi-Mustard procedure, and bidirectional cavopulmonary anastomosis was performed in two cases. During a mean follow-up period of 67 months (range three months to 18 years), we encountered one early postoperative mortality related to intracerebral bleeding. All but one of the patients are now in NYHA class I–II.** ***Conclusions:*** **Congenitally corrected transposition of the great arteries is a rare congenital cardiac anomaly in which the results of the anatomical repair with double switch operation appear to be superior to that achieved by a physiological repair.** doi: 10.1111/jocs.12728 *(J Card Surg 2016;XX:1–6)*

TABLE 1
Demographic, Operative, and Long-Term Outcomes

Patient	Age (months)	Body Weight (kg)	Associated Cardiac Pathology	Surgical Procedure Group 1, 2, 3*	Long-Term Outcomes
1	4	4.3	VSD, PDA	Group 1, PDA closure	Early postoperative mortality
2	5	4.9	VSD	Group 1	Mild to moderate AR, NYHA I
3	6	5.2	VSD, TR	Group 1	NYHA I
4	72	14	VSD (multiple)	Group 1	Mumps infection related LV dysfunction, NYHA II
5	49	9.6	VSD, Ebs, PS, TR, AV block	Group 3, PS repair, PM implantation	NYHA II
6	6	5	VSD, Ebs, TR, s/p PAB	Group 1, pulmonary debanding	Late Cx artery occlusion, NYHA I
7	18	10	VSD, Ebs, TR, coA	Group 1, coA repair	Mild to moderate AR, NYHA I
8	36	12	VSD, Ebs, TR, s/p PAB	Group 1, pulmonary debanding	NYHA I
9	48	16	VSD, PS	Group 2	Reoperation for early RV-PA conduit thrombosis, NYHA I
10	4	4.1	VSD	Group 3	Reoperation for pulmonary venous baffle stenosis, RF ablation, mild to moderate AR, NYHA I
11	60	18	VSD, PS	Group 2	NYHA III, scheduled for dual PM implementation
12	50	14	VSD, PS, s/p SPS	Group 2, division of the shunt	RV-PA conduit replacement, NYHA I
13	24	9.2	VSD, TR	Group 1	NYHA I
14	7	6.2	VSD	Group 1	NYHA I
15	5	5.1	VSD	Group 1	NYHA I
16	6	5	VSD, Ebs, TR, s/p PAB	Group 1, pulmonary debanding	Postoperative temporary mechanical circulatory support, mild to moderate AR, NYHA I

*Group 1: Atrial and arterial switch operation; group 2: atrial switch and Rastelli procedure; group 3: arterial switch and hemi-Mustard procedures, bidirectional cavopulmonary anastomosis.
VSD, ventricular septal defect; PDA, patent ductus arteriosus; TR, tricuspid regurgitation; Ebs, Ebstein anomaly; AV, atrioventricular; PS, pulmonary stenosis; PAB, pulmonary artery banding; CoA, coarctation of the aorta; SPS, systemic to pulmonary shunt; PM, pace-maker; RV, right ventricle; PA, pulmonary artery; AR, aortic regurgitation; LV, left ventricle; Cx, circumflex coronary artery; RF, radiofrequency ablation.

Olgular

- 1995-2016 tarihleri arasında anatomik düzeltme sağladığımız 16 CTGA olgusu mevcut. 21 yıllık kişisel deneyimi içeriyor.

- Yaş ortalaması 25 ay (4-72ay)
- Ağırlık ortalaması 8.9kg (4,3-19kg)
- 13 erkek, 3 kız
- Shunt: 1 hasta
- Pulmoner Banding: 3 hasta

Cerrahi teknikler

Arteryel switch + Senning olguları :11

- 10 olguda VSD.(Bir vakada multipl VSD)
- 6 hastada TY (4 Ebstein)
- 5 hastada Koroner anomali (3 tek koroner arter)
- 3 hastada PS
- 1 hastada dekstrokardi
- 1 hastada Aort Koarktasyonu ve PDA
- 1 preop tam AV blok
- 2 hastada WPW

Arteryel switch + Hemi- Mustard: 1

Rastelli + Senning: 3

- Bir hastada restriktif VSD ameliyatta genişletildi.

Rastelli + Hemi-Mustard: 1

Cerrahi Teknik

- 28°C Kardiyopulmoner bypass
- Ultrafiltrasyon
- Hipotermik antegrad kan kardiyoplejisi (15 dk aralıklı)

- Arteryel switch(ASO) + Senning grubundaki hastalarda VSD, transmitral yolla kapatılırken Senning + Rastelli grubundaki 3 hastada transmitral + sağ ventriküler yaklaşım uygulandı.

Cerrahi teknik

- ASO sırasında pulmoner anastomoz kısmen sol PA üzerine kaydırılarak pulmoner konstrüksiyon sırasında greft interpozisyonundan kaçınıldı. Bir hastada PA basısından korunmak için asendan aortaya 19 mm Vascutek greft interpoze edildi.
- Hiç bir hastaya Le Compte manevrası yapılmadı.
- Rastelli sırasında RV-PA devamlılığı için ilk vakada 16 mm Dacron ekstrakardiak konduit, ikinci vakada 21 mm Medtronic Freestyle, 3. vakada 18 mm Contegra kullanıldı.

Mod. Senning: Cerrahi teknik

- TY yoksa genellikle atriyumlar küçük
- Geniş ASD mevcutsa iç flep PTFE patch ile oluşturuldu.
- Dış flep genellikle otolog perikard (gluterald) ile büyütüldü.
- Autologous Senning prosedürü: insitu perikard ile pulm. venöz baffle rekonstrüksiyonu (Barrat-Boyes modifikasyonu)
  - 2 hastada kullanıldı

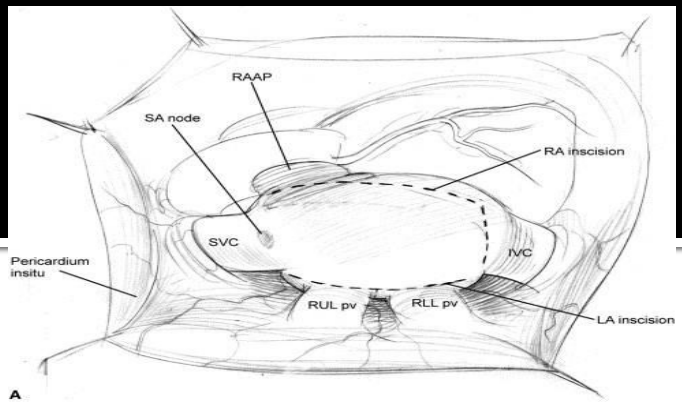

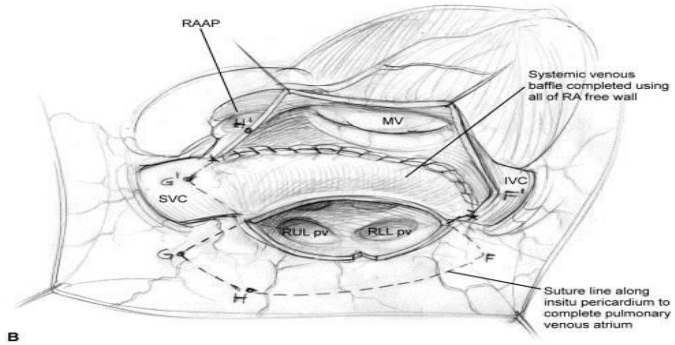

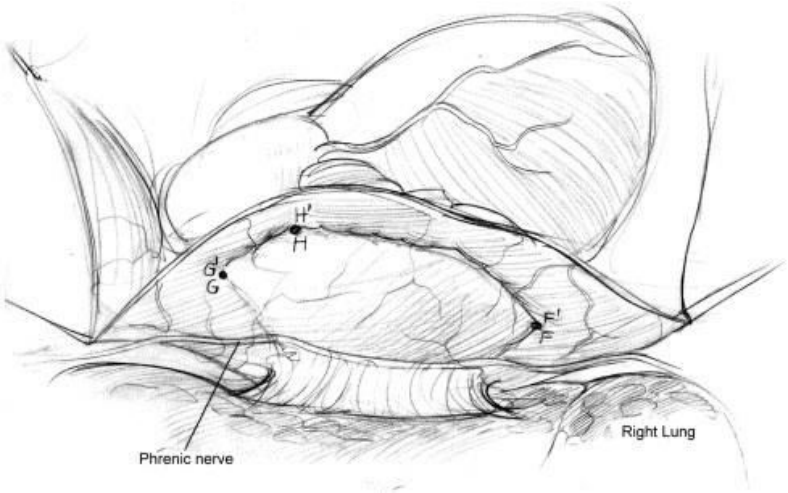

Postoperatif erken izlem

- Bir hastada mortalite görüldü(%6.25). Bu hasta hemodinamik olarak ve kardiyak açıdan sorunsuz seyretmesine rağmen hiç uyanmadı. BT ile beyinde yaygın kanama saptandı. 11. gün eksitus oldu.
- Sinüs ritminde KPB'dan çıkan bir hastada AV blok nedeniyle sonradan kalıcı pace implante edildi.
- Bir hasta pulmoner venöz yol obstrüksiyonu nedeniyle 3.gün reoperasyona alınıp Gore-Tex yamayla dış flep genişletildi.
- ASO + Senning uyguladığımız bir hasta 95/dk hızda AV blokla seyredip 15 gün sonra sinus ritmine döndü.
- Hemi-Mustard + Glenn uygulanan bir hastada Contegra konduitinde trombüs gelişmesi üzerine 1 ay sonra pompasız reoperasyon yapıldı.

Postoperatif geç izlem

- Takip süresi: ort.67 ay (3 ay-18 yıl). Bir hasta son yıllarda takip dışı kaldı.
- Hastaların biri hariç hepsi asemptomatik ve NYHA Class I-II durumunda izlenmektedir.
- NYHA class III durumdaki hastaya 17 yıl önce Rastelli ve Senning + kalıcı pace implantasyonu yapılmıştı. 8 yıl sonra RV-PA pulmoner homogreft replasmanı uygulandı.Biventriküler disfonksiyon gözlenmesi üzerine dual pacemaker planlandı.
- Senning + Arteryel Switch + VSD operasyonu yapılan bir hasta postop 8. yılda pulmonik venöz baffle obstrüksiyonu nedeniyle opere edildi. Bu hastaya ayrıca WPW için cerrahi RF ablasyon yapıldı. İşlemden 4 yıl sonra bir kez SVT tekrarı gözlendi.

Postoperatif geç izlem

- Altı yaşında Atrial ve Arteryel Switch kombinasyonu uygulanmış VSD+PH'lıbir hastada LV EF'si azalmış olarak bulundu (%50). Kabakulak enfeksiyonu sonrası ortaya çıkan bu tablo miyokarditle ilişkili düşünüldü. Bu hastanın anjiografik kontrolü normal, efor kapasitesi klas II idi. Bu hasta son yıllarda takip dışı kaldı.

- Arteryel Switch uygulanan bir hastada kontrol anjiosunda ayrı ostiumdan çıkan Cx 'in retrograd dolduğu gözlendi. Bu hasta asemptomatik olarak LVEF:%45-50 olarak izlenmektedir.

- Ekokardiyografik kontrollerde 4 hastada hafif AY tesbit edildi. Takip süresince AY'de ilerleme olmadı.

Diğer yöntemlerde deneyimimiz: 31 hasta (Son 5 yıl hariç)

- Mavroudis Yöntemi: 4 hasta.
  - Bir hastaya ekstrakardiyak konduit gerekti
- Pulmoner banding: 5 hasta
- VSD + Ekstra kardiyak konduit: 7
- VSD: 1 Hasta
- VSD+ PS giderme:1
- VSD +Triküspitplasti:1
- Triküspitplasti + Pulmoner banding:1
- MBTS: 2
- Fontan: 4 hasta (Hepsi LV hipoplazili)
- Bidir Glenn: 4
- Bidir Glenn + mitralplasti:1
- Mortalite görülmedi.

Fizyolojik tamir sonrası İlginç bir komplikasyon: Triküspit (sistemik kapak) korda rüptürü

- 7 y, E
- CTGA + VSD + PS
- Daha önce Ductal stent, sonra Restriktif EC conduit + LPA genişletilmesi op. uygulanmış
- VSD kapatılması + Konduit replasmanı (Pulmoner homogreft) ameliyatı sonrası problemsiz serviste taburculuğu planlanırken ani gelişen öksürük, solunum sıkıntısı ve akciğer ödemi ile YBÜ'ne alındı. EKO'da triküspit kapak korda rüptürü saptandı.
- Acil ameliyata alınarak artifisyel korda + anuloplasti uygulandı. Sorunsuz biçimde taburcu edildi.
- Konduit replasmanı sonrası, pulmonik ventrikül basıncında ani düşme sonucunda sol ventrikülün küçülmesi ve septumun sola kayması ile sistemik sağ ventrikülün dilatasyonunun triküspit tensor aparat üzerinde yarattığı gerginliğin buna sebep olduğunu düşünüyoruz.

Algorithm for the management of Congenitally Corrected Transposition

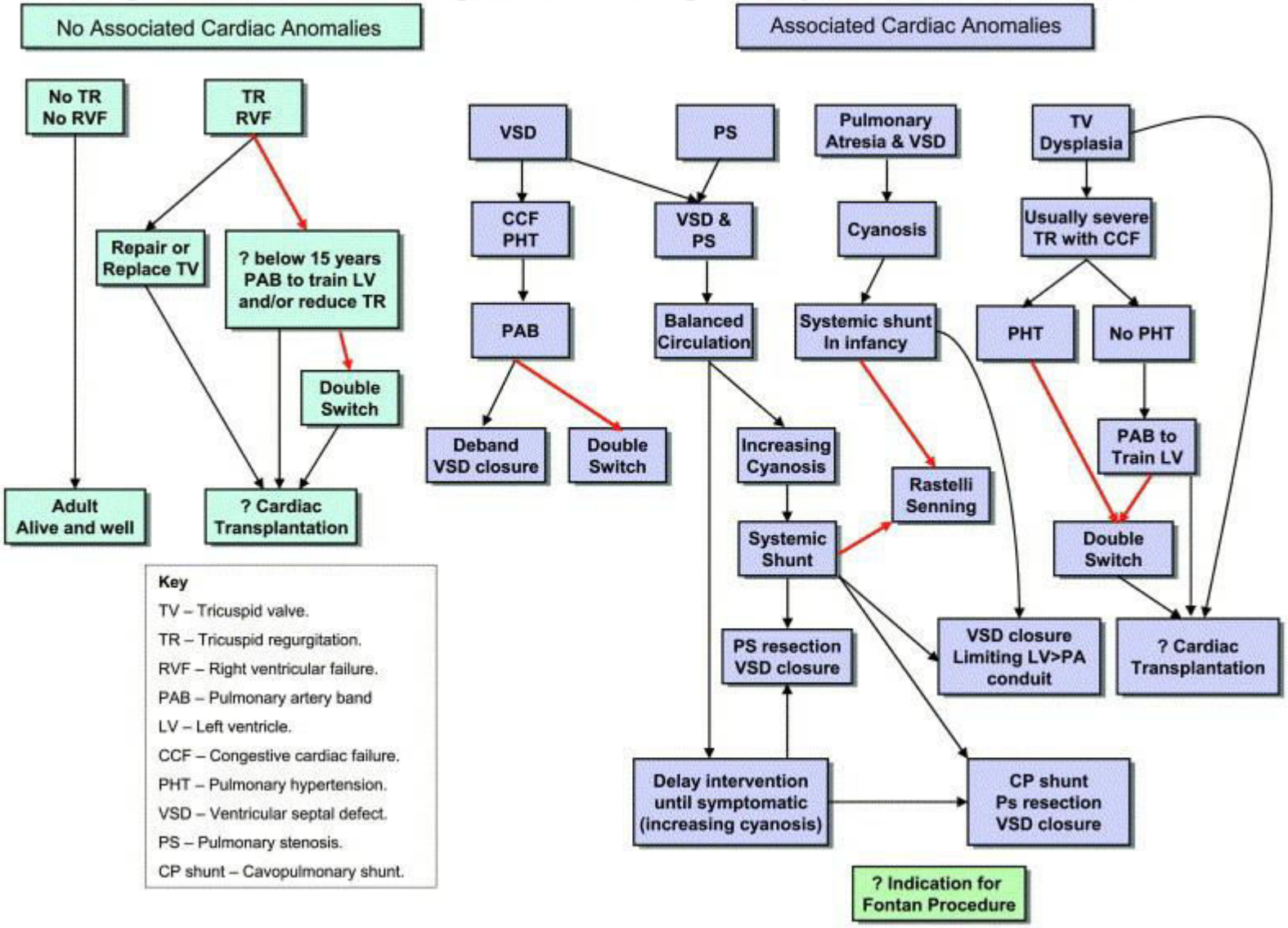

Sonuç

- Double Switch operasyonu CTGA'lı hastalarda Triküspit yetersizliğini gidermede çok etkili bir yaklaşımdır.
- Triküspit kapak anomalili, önemli Triküspit yetersizliği , sağ ventrikül yetmezliği olan C-TGA olgularında anatomik tamir tercih edilmelidir.
- İzole pulmoner banding ile sistemik AV kapak yetersizliği azalmakta veya en azından stabilize edilmekte, sistemik RV fonksiyonlarında düzelme sağlanabilmektedir.
- Aşamalı anatomik tamir planlanan vakalarda hasta yaşı prognozu belirlemede önemli rol oynar.
- Fizyolojik tamir yapılacaksa uygun vakalarda Mavroudis yöntemi ile konduit kullanımından kaçınılabilir.
- Biventriküler tamiri komplike kılan durumlarda Fontan iyi bir seçenek olabilir.

Senning+Arterial Switch

Daha az fizyolojik tamir, Daha çok double switch yapın. Fontan'ı da unutmayın!